



ASSOCIATION OF DRY EYE DISEASE WITH DIABETIC RETINOPATHY SEVERITY IN TYPE 2 DIABETES MELLITUS: AN OBSERVATIONAL STUDY

Dr. Surabhi Kumari¹, Dr.Prakriti Tripathi², Dr.Swati Gupta³

¹Senior Resident, Sanjay Gandhi Post graduate institute of Medical Sciences, Raebareilly Road, Lucknow shini.sur@gmail.com

²Senior Resident, Dr.Ram Manohar Lohia Institute of Medical Sciences, Gomti Nagar prakriti882@gmail.com

³Consultant, Eye Q Super-Speciality Eye Hospital, Gurugram Haryana, drswativerma010@gmail.com

Received:- 03/04/26

Revised:-05/05/26

Accepted:-20/05/26

Published:- 03/06/26

Abstract

Purpose

To evaluate the association between dry eye disease (DED) and severity of diabetic retinopathy (DR) in patients with type 2 diabetes mellitus (T2DM), and to assess the relationship between duration of diabetes and dry eye severity.

Methods

This cross-sectional observational study included 150 patients with type 2 diabetes mellitus attending the ophthalmology outpatient department of a tertiary care centre. All patients underwent detailed ophthalmic evaluation including Ocular Surface Disease Index (OSDI) questionnaire, Schirmer I test, Tear Film Break-Up Time (TBUT), fluorescein corneal staining, and fundus examination. Diabetic retinopathy was graded according to Early Treatment Diabetic Retinopathy Study (ETDRS) classification. Correlation between dry eye parameters and diabetic retinopathy severity was analyzed statistically.

Results

A significant association was observed between severity of diabetic retinopathy and severity of dry eye disease on Schirmer I test, TBUT, OSDI score, and corneal fluorescein staining ($p < 0.05$). Severe dry eye was more frequently observed in patients with severe non-proliferative diabetic retinopathy (NPDR) and proliferative diabetic retinopathy (PDR). Duration of diabetes also showed significant correlation with worsening dry eye parameters ($p < 0.001$). Patients with diabetes duration greater than 10 years demonstrated more severe tear film dysfunction and ocular surface abnormalities.

Conclusion

Dry eye disease severity increases with worsening diabetic retinopathy and longer duration of diabetes mellitus. Ocular surface evaluation should be considered an important component of routine diabetic eye assessment, particularly in patients with advanced diabetic retinopathy.

Keywords- Dry eye disease, diabetic retinopathy, diabetes mellitus, tear film dysfunction, OSDI, TBUT

Introduction

Diabetes mellitus (DM) is a chronic metabolic disorder associated with significant systemic and ocular complications. Diabetic retinopathy (DR) remains one of the leading causes of preventable blindness worldwide. [1,2] In addition to retinal involvement, diabetes also affects the ocular surface and tear film, leading to dry eye disease (DED).[3] Dry eye disease is a multifactorial disorder characterized by tear film instability, ocular discomfort, visual disturbance, and inflammation of the ocular surface.[4] Diabetes-associated ocular surface dysfunction may result from autonomic neuropathy, microvascular abnormalities, lacrimal gland dysfunction, reduced corneal sensitivity, and inflammatory alterations.[5,6] Previous studies have demonstrated a higher frequency of dry eye disease in diabetic patients compared to non-diabetic individuals. [7,8] Several authors have also reported that severity of dry eye correlates with duration of diabetes and severity of diabetic retinopathy. [9,10] Diabetic retinopathy and dry eye disease may share common pathogenic mechanisms including chronic hyperglycemia-induced microvascular damage and neural dysfunction.[11] Progressive retinal disease may therefore reflect similar progressive involvement of the ocular surface. Despite increasing evidence linking diabetic retinopathy and ocular surface disease, dry eye evaluation is often overlooked during routine diabetic ophthalmic assessment. Early recognition of tear film abnormalities may improve patient comfort, visual quality, and ocular surface health.[12] The present study was conducted to evaluate the association between dry eye disease and severity of diabetic retinopathy in patients with type 2 diabetes mellitus and to assess the relationship between duration of diabetes and severity of dry eye disease.

Materials and Methods

Study Design

This cross-sectional observational study was conducted in the Department of Ophthalmology of a tertiary care teaching hospital after approval from the Institutional Ethics Committee. The study adhered to the tenets of the Declaration of Helsinki.

Study Population

A total of 150 patients diagnosed with type 2 diabetes mellitus were included after obtaining informed consent.

Inclusion Criteria

- * Patients diagnosed with type 2 diabetes mellitus
- * Age >18 years
- * Patients willing to participate

Exclusion Criteria

- * Previous ocular surgery
- * Contact lens wear
- * Ocular surface disorders unrelated to diabetes
- * Chronic allergic conjunctivitis
- * Herpetic eye disease
- * Use of topical medications affecting tear film

Ophthalmic Examination

All patients underwent detailed ophthalmic examination including:

- * Best corrected visual acuity assessment
- * Slit lamp biomicroscopy
- * Intraocular pressure measurement
- * Fundus examination with 90D lens after pupillary dilation

Diabetic retinopathy was graded according to ETDRS classification into:

- * No DR
- * Mild NPDR
- * Moderate NPDR
- * Severe NPDR
- * Proliferative diabetic retinopathy (PDR)

Dry Eye Evaluation

Ocular Surface Disease Index (OSDI)

Dry eye symptoms were assessed using the OSDI questionnaire.[13]

The scores classified ≤ 12 as normal, 13-22 as mild, 23-32 as moderate, ≥ 33 as severe

Schirmer I Test

Schirmer I test without anesthesia was performed using standardized strips for 5 minutes.[14] Dry eye severity based on Schirmer I test was classified as follows:

NORMAL	if wetting is $>10\text{mm}$
MILD DRY EYE	if wetting is from 6 to 10mm
MODERATE DRY EYE	if wetting is from 2-5mm
SEVERE DRY EYE	if wetting is from $<2\text{mm}$

Tear Film Break-Up Time (TBUT)

TBUT was measured after fluorescein instillation under cobalt blue illumination.[15]

TBUT findings were classified as:

NORMAL	TBUT $>10\text{SEC}$
MARGINAL	TBUT 5 TO 10 sec
LOW	TBUT <5 sec

Corneal Fluorescein Staining

Corneal staining was graded using OSS SICCA grading system.[16]

If one to five PEEs are seen, the corneal score is 1;

6 to 30 PEEs are scored as 2;

and >30 PEEs are scored as 3.

An additional point is added if:

- (1) PEEs occurred in the central 4-mm diameter portion of the cornea,
- (2) one or more filaments are observed anywhere on the cornea, or
- (3) one or more patches of confluent staining, including linear stains, are found anywhere on the cornea. The maximum possible score for each cornea is 6.

Statistical Analysis

Data were analyzed using Microsoft Excel and statistical software. Chi-square test was applied to assess correlation between dry eye parameters and severity of diabetic retinopathy. A p value <0.05 was considered statistically significant.

Results

A total of 150 patients with type 2 diabetes mellitus were included in the study. Mean age of participants was 55.47 ± 10.29 years. Males constituted 54.7% of the study population. A statistically significant association was observed between duration of diabetes and severity of dry eye disease on Schirmer I test, TBUT, and OSDI score ($p < 0.001$). Patients with diabetes duration greater than 10 years demonstrated more severe dry eye findings compared to patients with shorter disease duration. On Schirmer I testing, severe dry eye was most frequently observed in patients with diabetes duration exceeding 10 years. Similarly, TBUT values showed progressive deterioration with increasing duration of diabetes. OSDI scores also demonstrated significant worsening with increasing duration of diabetes mellitus. A significant correlation was found between severity of diabetic retinopathy and severity of dry eye disease. Patients with severe NPDR and PDR demonstrated significantly reduced Schirmer I values and more severe aqueous tear deficiency compared to patients with mild or no retinopathy. (Table 1) On Tear Film Break-Up Time evaluation Moderate-to-severe tear film instability was significantly more common in patients with advanced diabetic retinopathy ($p < 0.001$). (Table 2) Higher OSDI symptom scores were observed in patients with severe NPDR and PDR compared to patients with mild diabetic retinopathy. (Table 3) Severity of corneal surface staining increased proportionately with severity of diabetic retinopathy, suggesting progressive ocular surface epithelial compromise. (Table 4)

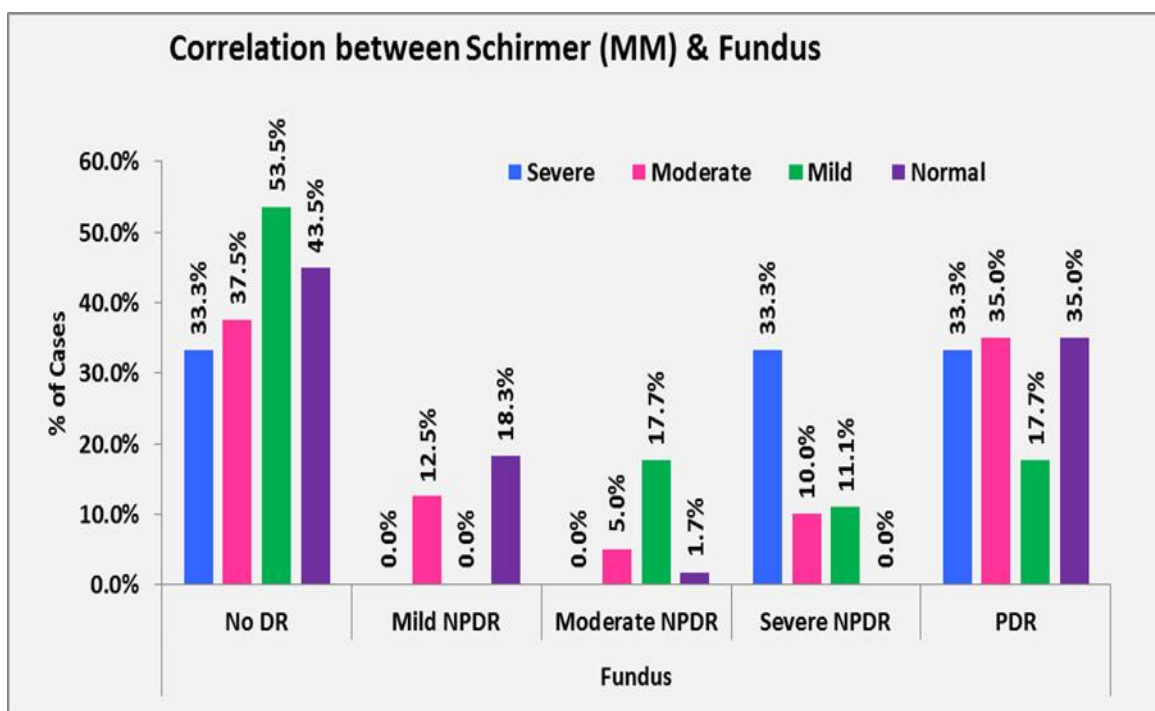


Table 1: Association between Diabetic Retinopathy Severity and Schirmer I test values

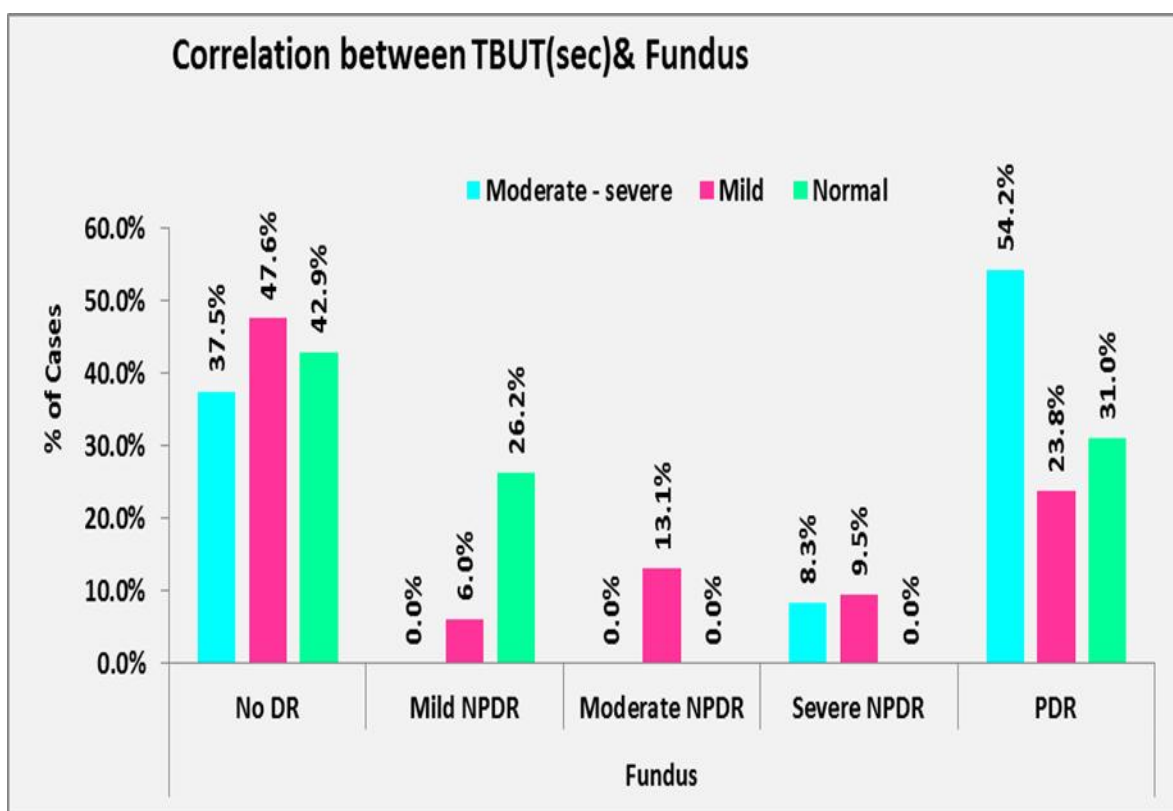


Table 2: Association between diabetic retinopathy severity and TBUT values

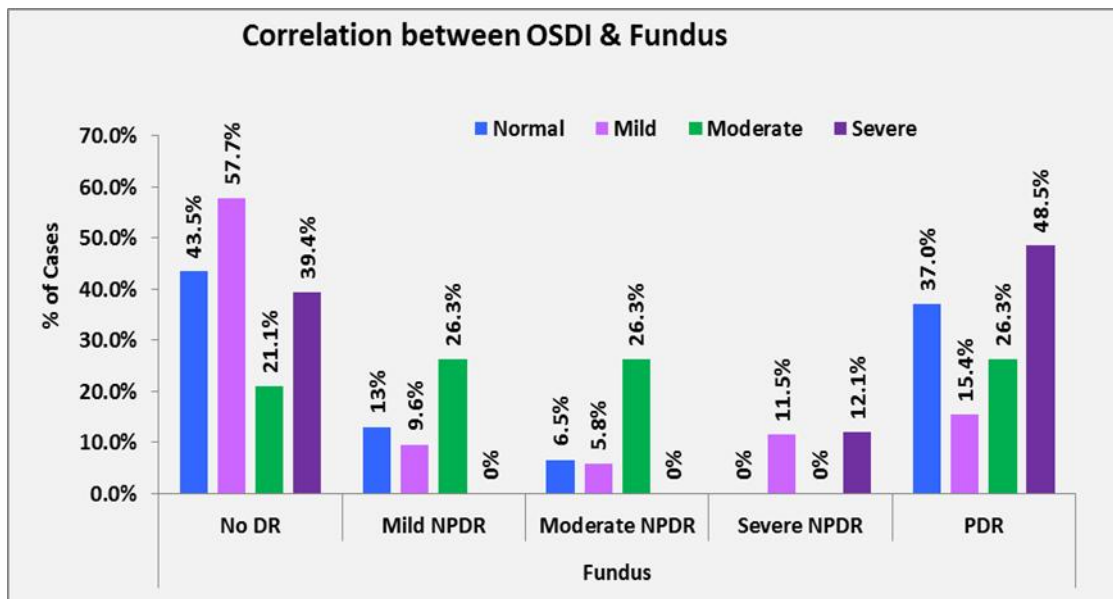


Table 3: Association between diabetic retinopathy severity and OSDI score

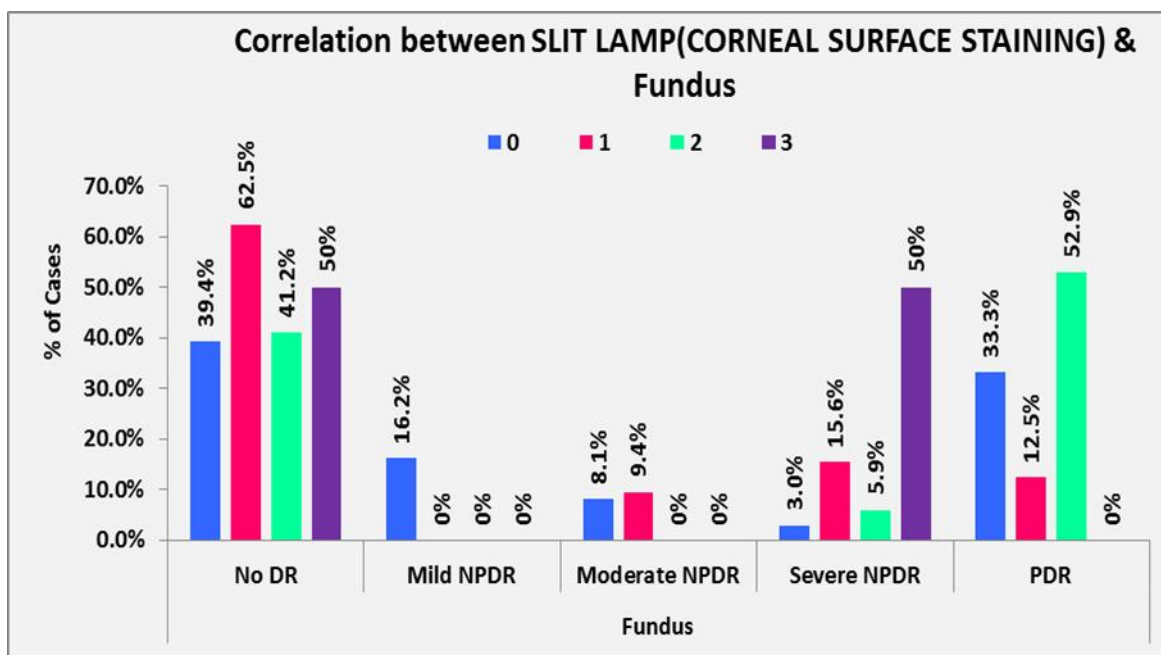


Table 4: Association between diabetic retinopathy severity and corneal surface staining

Discussion

The present study demonstrated a significant association between dry eye disease severity and diabetic retinopathy in patients with type 2 diabetes mellitus. Diabetes mellitus is known to affect the ocular surface through multiple mechanisms including autonomic neuropathy, microvascular compromise, lacrimal gland dysfunction, and inflammatory alterations.[5,6] Chronic hyperglycemia may also impair corneal innervation and tear film homeostasis. In the present study, severity of dry eye increased with progression of diabetic retinopathy. Patients with severe NPDR and proliferative diabetic retinopathy showed significantly worse Schirmer values, TBUT, OSDI scores, and corneal staining findings. Similar observations have been reported by Zhang et al. and Najafi et al., who demonstrated a strong association between ocular surface dysfunction and diabetic microvascular complications. [9,10] The present study also demonstrated significant correlation between duration of diabetes and dry eye severity. Patients with diabetes duration greater than 10 years showed more severe tear film dysfunction and ocular surface abnormalities. Prolonged exposure to hyperglycemia may contribute to progressive lacrimal gland dysfunction and corneal neuropathy.[17] TBUT

abnormalities observed in patients with advanced diabetic retinopathy suggest instability of the tear film and possible goblet cell dysfunction. Similar findings have been described by Yoon et al. in diabetic patients with ocular surface disease.[18] Corneal fluorescein staining increased with worsening diabetic retinopathy severity, indicating progressive epithelial damage in advanced diabetes. Gao et al. also demonstrated increased corneal epithelial injury in patients with proliferative diabetic retinopathy.[19] These findings support the hypothesis that diabetic retinopathy and dry eye disease may represent parallel manifestations of chronic diabetic microvascular and neural damage.

Limitations of the Study

1. This was a single-centre hospital-based study, which may limit generalizability of findings.
2. Glycemic control parameters such as HbA1c levels were not analyzed.
3. Advanced tear film investigations such as tear osmolarity and meibography were not available.
4. The study design was cross-sectional; therefore, causal relationship could not be established.
5. Follow-up evaluation was not performed to assess progression of dry eye disease over time.

Conclusion

Severity of dry eye disease increases with worsening diabetic retinopathy and longer duration of diabetes mellitus. Patients with severe NPDR and proliferative diabetic retinopathy demonstrate greater tear film dysfunction and ocular surface abnormalities. Routine dry eye evaluation should therefore be incorporated into comprehensive ophthalmic assessment of diabetic patients, especially those with advanced diabetic retinopathy.

References

1. Wild S, Roglic G, Green A, Sicree R, King H. Global prevalence of diabetes: estimates for the year 2000 and projections for 2030. *Diabetes Care*. 2004;27(5):1047-1053.
2. Anjana RM, Pradeepa R, Deepa M, et al. Prevalence of diabetes and prediabetes in urban and rural India. *Diabetologia*. 2011;54:3022-3027.
3. Ghasemi H, Gharebaghi R, Heidary F. Diabetes as a possible predisposer for blepharitis. *Can J Ophthalmol*. 2008;43(4):485.
4. Craig JP, Nichols KK, Akpek EK, et al. TFOS DEWS II definition and classification report. *Ocul Surf*. 2017;15(3):276-283.
5. Dogru M, Katakami C, Inoue M. Tear function and ocular surface changes in diabetes mellitus. *Ophthalmology*. 2001;108:586-592.
6. Goebbels M. Tear secretion and tear film function in diabetic patients. *Br J Ophthalmol*. 2000;84:19-21.
7. Seifart U, Stempel I. The dry eye and diabetes mellitus. *Ophthalmologie*. 1994;91:235-239.
8. Manaviat MR, Rashidi M, Afkhami-Ardekani M, Shoja MR. Prevalence of dry eye syndrome and diabetic retinopathy in type 2 diabetic patients. *BMC Ophthalmol*. 2008;8:10.
9. Zhang X, Zhao L, Deng S, Sun X, Wang N. Dry eye syndrome in patients with diabetes mellitus. *Ophthalmology*. 2016;123(4):784-791.
10. Najafi L, Malek M, Valojerdi AE, et al. Dry eye and diabetic microvascular complications in type 2 diabetes mellitus. *J Diabetes Complications*. 2013;27:459-462.
11. Kamel SS, Mohammed AS. Tear film changes in diabetic patients. *Delta J Ophthalmol*. 2017;18:12-18.
12. Yazdani-Ibn-Taz MK, Han MMK, et al. Dry eye severity and quality of life in diabetes mellitus. *BMC Ophthalmology*. 2019;19:223.
13. Schiffman RM, Christianson MD, Jacobsen G, Hirsch JD, Reis BL. Reliability and validity of OSDI questionnaire. *Arch Ophthalmol*. 2000;118:615-621.
14. Jordan A, Baum J. Basic tear flow. *Ophthalmology*. 1980;87(9):920-930.
15. Yoon KC, Im SK, Seo MS. Changes of tear film and ocular surface in diabetes mellitus. *Korean J Ophthalmol*. 2004;18:168-174.
16. Whitcher JP, Shiboski CH, Shiboski SC, et al. A simplified quantitative method for assessing keratoconjunctivitis sicca. *Arthritis Rheum*. 2010;62:2561-2569.
17. Li HY, Pang GX, Xu ZZ. Tear film function in type 2 diabetes mellitus. *Zhonghua Yan Ke Za Zhi*. 2004;40:10-13.
18. Yoon KC, Im SK, Seo MS. Tear film and ocular surface changes in diabetic patients. *Korean J Ophthalmol*. 2004;18:168-174.
19. Gao Y, et al. Ocular surface changes in type 2 diabetes mellitus with proliferative diabetic retinopathy. *Cornea*. 2015;34:142-14