

## DIAGNOSTIC VALUE OF FROZEN SECTION COMPARED TO PERMANENT PATHOLOGY IN CAUSTIC INGESTION

Esmail Hajinasrollah<sup>1\*</sup>

<sup>1</sup>Professor of General Surgery Shahid Behshti University of Medical Science Loghman Medical Center

\*Corresponding Author:-

Tel: + 98912 113 4049 Fax: + 9821 55419390

---

### Abstract:-

#### Introduction:-

Endoscopy is mandatory for assessment of severity of esophageal and gastric damage after corrosive burns. There are various mucosal damage classifications, which are unreliable for surgical decision making. Confirmation of endoscopic methods of burn depth estimation with pathologic findings is lacking. Faulty resection of burned esophagus and stomach based on mucosal damage also may be done. Second look has its own problem, and diagnostic doubt may still remain because intra-operative findings have not enough validity for decision making. New modality for rapid and accurate assessment of injury depth may be frozen section.

#### Method and materials

This is a blinded prospective study to evaluate the accuracy of frozen section in estimation of burn depth. Fifty one patients with grade 2 or 3 mucosal burn due to caustic injury underwent surgical exploration and biopsy taking. Samples reported by two pathologists. Grading of samples either frozen section or permanent compared to each other. Intraoperative judgment of the surgeon compared with pathologic findings. Interrater reliability of examinations compared to each other by the kappa statistic.

#### Results

Biopsy samples of fifty one patients with mean age of 33.4 years evaluated and compared to intra-operative findings. Thirty seven patients graded 2 and fourteen were in grade 3 endoscopy. At grade three, only 5 cases had the entire thickness of the stomach burn. Also, from 10 cases of gastrosophagectomy, 5 cases had mucous and under-mucous membranes burn. There were so many variations between pathologic diagnosis of burn depth and judgment of the surgeon ( $\kappa < 0.2$ ).

#### Conclusion:

Frozen section examination can be an accurate tool for final decision making in corrosive ingestion. Second look surgical exploration can be ignored from the management plan. Intraoperative opinion of a surgeon for estimating necrosis is not accurate. Futile resections are preventable, and limited resection based on frozen section examination of burn margins will be possible. Limited resection probably made later reconstruction more feasible.

**Keywords:** caustic ingestion, Frozen Section, Permanent Section, Pathology, high degree burns

## INTRODUCTION :-

Caustic ingestion is one of the most common options of the suicidal attempts in our country. Upper gastrointestinal endoscopy is the primary step for decision making in corrosive ingestion. Mucosal grading of injury depth has been prognostic value<sup>1,2</sup>. There are many grading systems for evaluation of burn depth<sup>3,4, and 5</sup>. There is not enough data to determine the accuracy of endoscopy for surgical exploration and resection. However, high grade burns are the basis for surgical decision making. Intra-operative histopathological evaluations play a key role in diagnosis of caustic ingestion since the clinical presentation and radiologic findings in these lesions do not provide sufficient information and a definite diagnosis relies upon the histopathological findings<sup>6</sup>. Surgical resection of damaged esophagus or stomach is best guided by pathologic examination of a full thickness biopsy which is not readily accessible during surgery. Intraoperative findings such as tissue consistency and color have not defined yet and reliability of the surgeon judgment for diagnosis of necrosis is minimal. Futile resection of stomach and esophagus based on endoscopic and intra-operative tissue examination may happen and is preventable. <sup>7,8</sup> Second look exploration may be unsatisfactory. The Readily accessible and accurate diagnostic tool required <sup>8</sup>. An intra-operative diagnostic method should be able to provide the diagnosis within minutes, preserving a considerable proportion of the specimen for analysis by the gold standard method. Accordingly, we aimed to assess the compatibility between results of frozen section analysis and permanent section analysis in patients with caustic injury in loghman Hakim Hospital.

## Material and methods

This is a blinded prospective study of fifty one patients with corrosive ingestion. Patients with endoscopy grading of 2 or 3 include. After surgical exploration posterior gastric wall biopsied. In study, patients made through histopathological evaluations were identified by reviewing the pathology reports documented in the department of pathology of loghman Hakim Hospital during 2009-2013. Of these patients, subjects who had undergone a frozen section analysis of the caustic ingestion and their diagnoses were recorded based on the findings of the gold standard method were included as the study population. Seventy cases Grade 0 and one hundred cases Grade 1 were excluded from the study Tissue samples sectioned and stained with hematoxylin, and eosin dyes. Pathologists invited for examination of the sections' which are tagged with secret codes. Reports of each section were based on skin burn grading. Surgeon judgment and endoscopic scale of burn recorded separately. Pathologic Reports of each patient (frozen and permanent sections), and report of each section (between two pathologist) analyzed. Surgeon's intra-operative scale of burn compared to endoscopic and pathologic one. Interrater reliability of surgical findings analyzed by kappa statistics. In order to assess the sources of discrepancies between permanent and frozen section analyses, an experienced pathologist interested in neuropathology, blinded to previous diagnoses, re-evaluated the available slides. The diagnoses made by this pathologist were compared to previous results of both frozen section and permanent analyses and accordingly the possible sources of discrepancies were identified.

## Statistical Analysis:

Data were analyzed using SPSS software version 24 .For qualitative and quantitative variables, the absolute and relative variables were recorded. Kappa statistics test were used to compare the two groups.

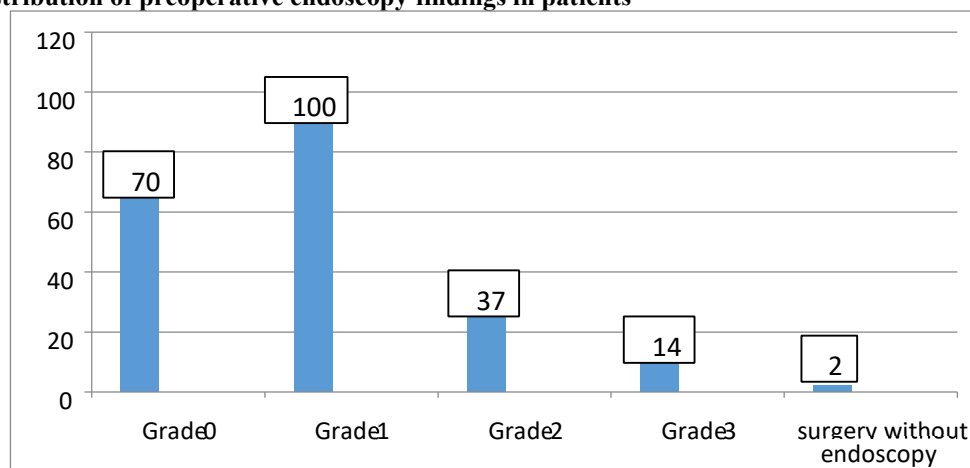
## Ethical issues

The research followed the tenets of the Declaration of Helsinki. All patients signed a written informed consent form to participate in the study. This project was also approved by the Ethics committee of Shahid Beheshti university of Medical Sciences.

## Results:

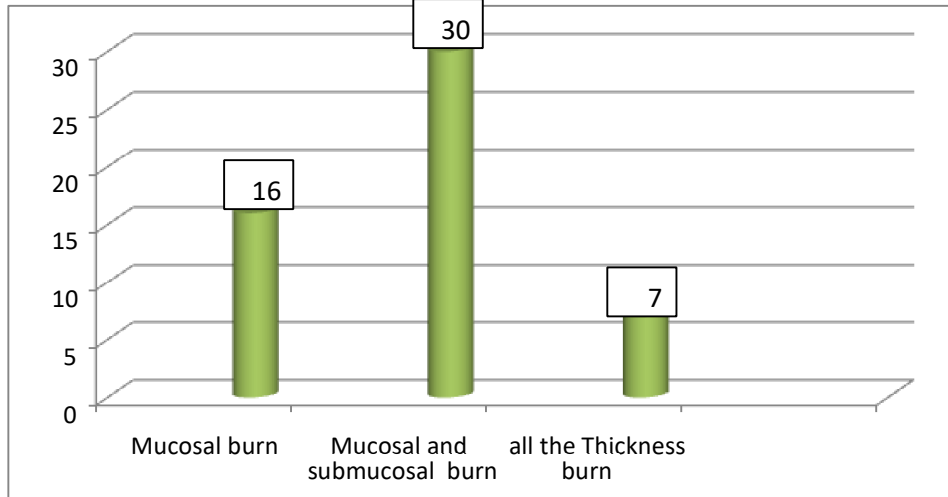
In a blinded prospective study, fifty one patients had a high grade endoscopic mucosal damage (Grade 2 and 3 goldsmiths) due to intentional caustic ingestion (37 cases were grade 2 and 14 were grade 3). The mean age of these patients were 33.4 years old .The patients were examined by laparotomy (Fig. 1).

Figure 1. Distribution of preoperative endoscopy findings in patients



During the laparotomy, 10 cases were subjected to gastrosophagectomy due to the full thickness burn and the 37 cases were also underwent to esophageal stent placement. Also, 4 cases were candidates for the second look, which were subjected to re-laparotomy. Also, 1 case due to evidence of acute mediastinitis (neck amphysea) and 1 case due to peritonitis (board like abdomen) without endoscopy were under laparotomy and gastrosophagectomy. All 53 cases were sent for pathology of Frozen and Permanent. Frozen experiments showed that, 16 cases of mucosal burns (grade 1), 30 mucous membranes and submucosal burns, and 7 cases of transmural burn [grade 3] (Fig. 2).

**Figure 2. Distribution of furozan and laparotomy pathological findings in patients**



The results of permanent pathology as a golden standard confirmed the results of Frozen. The relative frequency of frozen pathology results based on the endoscopic grade is presented in Table 1.

**Table 1. Relative frequency of furozan pathological findings based on endoscopic grade**

total	Without endoscopy	Grade 3	Grade 2	
16	0	3	13	Grade 1
30	0	6	24	Grade 2
7	2	5	0	Grade 3
	2	14	37	total

There is no difference in permanent and frozen section examination for injury depth. Both pathologists had an identical diagnosis about the depth of injury ( $\kappa > 0.9$ ). Agreement between surgeon judgment about burn scale and pathologic finding was poor ( $\kappa < 0.02$ ).

**Discussion:**

Frozen section analysis is a common histopathological diagnostic method used during surgical procedures performed on patients with caustic ingestion. One of the reasons for its extensive use is that frozen section analysis is a fast method that can provide surgeons with determinative information for the treatment of patients during the surgical procedure, which is utmost important particularly in high risk surgeries such as craniotomies<sup>9,10</sup>. Moreover, while sending the specimens for frozen section analysis, the pathologist can evaluate the remainder of the specimen for later permanent section analysis, which becomes more prominent with the improvements of stereotactic biopsy methods in caustic ingestion and if the pathologist declares insufficiency of the remaining specimen, the surgeon can take more biopsies from the tumor in the same session<sup>11,12,13</sup>. Caustic ingestion is the issue of controversy. Treatment plane is based on endoscopic findings. Upper endoscopy is the available and valuable diagnostic tool for evaluation of mucosal injury but with the limited capability to estimate the depth of injury. Esophageal and gastro-intestinal burns are a diagnostic problem at the stage of judgment and